pubvet
MEDICINA VETERINÁRIA E ZOOTECNIA
ISSN 1982-1263
https://doi.org/10.31533/pubvet.v19n11e1863

First double cervical implant in a horse in Latin America

Luiz Alberto da Silva Vasconcellos[1], Beatriz André Marques[1], Caio Ferrari Teixeira[1], Carolina Frederico Sciacco[1], Cauane do Carmo Souza[1], Eduarda Barreira Carvalho[1], Gabriel Vieira Rocha[7], João Vitor da Paixão Buono[1], Raphel Augusto da Silva Hernandez[1], Roberta Sargo[1], Thiago Escodro Dercoli[1]

[1]Centro de Medicina Equina Integrado, Araçatuba, São Paulo, Brasil.
**Corresponding author, e-mail: luizalbertovasconcellos@gmail.com.*

Abstract. An 11-year-old Quarter Horse mare used for barrel racing, weighing 435 kg, presented with severe ataxia (grade 4). She was initially treated for pelvic and lumbar disorders and for Equine Protozoal Myeloencephalitis (EPM). However, there was no clinical improvement and no definitive diagnosis was reached. A thorough clinical and neurological examination, together with cervical radiography and contrast myelography, revealed cervical spinal cord compression at the C2–C3 and C3–C4 segments. Surgical treatment was selected, consisting of vertebral fusion (cervical arthrodesis) of the affected segments using a Brazilian metal implant. This procedure, the first double cervical fusion performed in Latin America, was successful.

Keywords: Ataxia, compressive cervical myelopathy, equine cervical fusion, metal implant, neurological disease, wobbler syndrome.

Primeiro implante cervical duplo em um equino na América Latina

Resumo. Uma égua da raça Quarto de Milha, de 11 anos, utilizada em provas de tambor e pesando 435 kg, apresentou ataxia severa (grau 4). Inicialmente, foi tratada para distúrbios pélvicos e lombares e para mieloencefalite protozoária equina (EPM). No entanto, não houve melhora clínica e nenhum diagnóstico definitivo foi obtido. Um exame clínico e neurológico detalhado, associado à radiografia cervical e à mielografia contrastada, revelou compressão medular cervical nos segmentos C2–C3 e C3–C4. Optou-se pelo tratamento cirúrgico, consistindo na fusão vertebral (artrodese cervical) dos segmentos afetados com o uso de um implante metálico brasileiro. Este procedimento, o primeiro implante cervical duplo realizado em um equino na América Latina, foi bem-sucedido.

Palavras-chave: Ataxia, mielopatia cervical compressiva, fusão cervical equina, implante metálico, doença neurológica, síndrome do wobbler

Introduction

The first description of incoordination in horses referred to a disease that primarily affected horses up to two years of age, racehorses, and riding horses. Bilateral signs of ataxia were observed in the hind limbs, possibly associated with cervical pain, vertebral abnormalities, foraminal stenosis, and nerve root compression. Numerous hypotheses were proposed regarding the cause of this incoordination, later known as "wobbler," resulting from instability in posture or gait (Dimock & Errington, 1939).

From that point onward, several possible etiologies were investigated, including genetic diseases (Dimock, 1950; Errington, 1938; Falco et al., 1976), metabolic disorders (Glade & Belling, 1984; Glade & Luba, 1987), nutritional deficiencies (Hurtig et al., 1993; Knight et al., 1985, 1990; Kronfeld et al.,

1990; Mayhew, 2009), degenerative diseases (Hurtig et al., 1993; May-Davis et al., 2024), cervical malformations (Derouen et al., 2016; May-Davis, 2014; Santinelli et al., 2016; Vasconcellos, 2024; Watson & Mayhew, 1986), and traumatic causes (May-Davis et al., 2024; Nixon & Stashak, 1988; Pinchbeck & Murphy, 2001; Vasconcellos, 2025).

Cervical vertebral stenotic myelopathy (CVSM) is a common cause of ataxia or "wobbler" in horses and other species. CVSM is characterized by ataxia and weakness caused by narrowing of the cervical spinal canal and compression of the spinal cord, often accompanied by malalignment or malformation of the cervical vertebrae (Dyson et al., 2024; May-Davis et al., 2024). Spinal canal stenosis, occurring anywhere from the first cervical vertebra (C1) to the first thoracic vertebra (T1), represents the principal abnormality in CVSM. CVSM is the main cause of "Wobbler's Syndrome," with older synonyms including equine sensory ataxia, equine incoordination, and spinal ataxia. It is the leading cause of noninfectious spinal ataxia in horses and has also been identified in other breeds, such as Arabians, Morgans, Appaloosas, Quarter Horses, Brazilian breeds, and Mangalargas (Vasconcellos, 1995, 2024). Males are more frequently affected than females (Furr et al., 2015; Vasconcellos, 1995, 2022, 2024, 2025).

The diagnosis of ataxia or wobbler syndrome in horses is based on several factors, including family and breed predisposition, coat color, age, purpose, and feeding regimen. A thorough history and clinical examination are essential, as neurological deficits can help localize the lesion by identifying focal or diffuse atrophies, lameness unresponsive to nerve blocks, asymmetry between right and left or fore and hind limbs, gait abnormalities (hypermetria, hypometria, or dysmetria), and altered skin sensitivity (hyperesthesia or anesthesia) (Andrews et al., 1990). These findings assist in lesion localization and guide the use of ancillary diagnostic methods, such as serology, cerebrospinal fluid analysis, radiography, thermography, computed tomography (CT), and magnetic resonance imaging (MRI) (Furr et al., 2015; Vasconcellos, 1996, 2022).

Currently, the most effective and commonly used diagnostic technique is contrast myelography, a radiographic procedure performed with or without a robotic radiography device capable of producing three-dimensional "multi-slice" images without the need for contrast injection or anesthesia. Through the injection of iodine-based contrast into the dural space, it is possible to locate the site or region of spinal cord compression and decide whether clinical, surgical, or euthanasia treatment is indicated (De Lahunta et al., 2020; Summers et al., 1995). Computed tomography and robotic radiography provide 3D images in sagittal, longitudinal, and transverse planes with higher precision than conventional myelography. However, due to their high cost and limited availability for equine use worldwide, these techniques are not yet routine (Andrews et al., 1990; Furr et al., 2015; Veraa et al., 2016). A limitation of contrast myelography is the need to perform the procedure under general anesthesia, with the horse's head elevated approximately 45 degrees relative to the body. Thus, it is not recommended for severely ataxic horses, as they may be unable to stand after the procedure (De Lahunta et al., 2020; Summers et al., 1995; Vasconcellos, 2022).

The most effective treatment for horses with wobblers involving cervical trauma leading to instability, spinal cord compression, and canal stenosis is arthrodesis, the fusion of two or more cervical vertebrae using implants or bone grafts. This technique, utilized by Seo et al. (2023), has been applied in both humans and animals. Initially, arthrodesis employed autologous bone grafts to replace the intervertebral disc, promoting osteoarthritis and subsequent joint fusion, but often resulting in limited cervical stability.

The first successful equine surgery using this technique was reported by Wagner et al. (1979), after which numerous horses underwent the procedure. From this, orthopedic surgeon (Bagby, 1988), who participated in the first surgery, developed a metal implant known as the "Bagby Basket Steel Implant."

In Brazil, the first cervical arthrodesis was performed on a foal in 1992 by Vasconcellos (1996), who later published a new surgical technique in 1996 for horses with cervical spinal cord compression, achieving a high success rate despite the difficulty of obtaining the original cervical implant.

In October of 2024, Vasconcellos (2025) performed the hundredth cervical arthrodesis on a *Brasileiro de Hipismo* foal in Brazil. The surgery was successful and utilized a novel implant developed by the author himself, the Brazilian Metallic Implant (Vasconcellos, 2025).

The objective of this study is to describe the first reported case of double cervical arthrodesis in a horse in Latin America, using a Brazilian metallic implant. It outlines the diagnostic process, surgical technique, and postoperative outcome. The report aims to expand clinical and surgical understanding of cervical vertebral instability in horses.

Material and methods

An 11-year-old Quarter Horse mare, weighing approximately 425 kg and used for barrel racing, presented with severe ataxia (grade 4), with no relevant clinical history. The attending veterinarian requested a consultation due to the animal's complex clinical condition and unclear case history. Two other professionals had previously suggested lumbosacral ligament injury and lower back pain as possible causes. Based on these findings, anti-inflammatory therapy was initially prescribed. However, due to minimal clinical response, treatment for Equine Protozoal Myeloencephalitis (EPM) was subsequently initiated and continued for 30 days.

Following a detailed clinical and neurological examination performed by the team, a cervical vertebral malformation associated with dynamic cervical vertebral instability (wobbler syndrome) was suspected (Figure 1A). Radiographic evaluation did not confirm cervical spinal cord compression but revealed a vertebral malformation at C1 (Figure 1B). After discussion among the team, the attending veterinarian, and the horse's owner, it was decided to perform a contrast myelography under general anesthesia to confirm the diagnosis (De Lahunta et al., 2020; Summers et al., 1995; Vasconcellos, 1995, 2022).

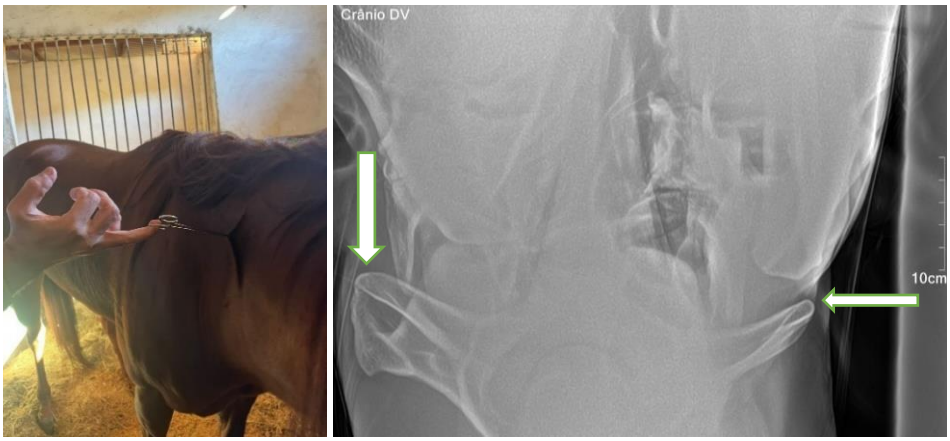

Figure 1. A: Observe the skin anesthesia in the region suspected of spinal cord compression and **B:** shows the bilateral disharmony of C1 (dorsoventral projection/white arrows).

After contrast myelography, spinal cord compression was confirmed at two points C2-C3 and C3-C4 (Figures 2). In this case, instead of a single compression point, two points were found, characterizing double cervical vertebral instability. Associated with the clinical picture and spinal cord compression points shown by myelography, surgery or arthrodesis between C2-C3 and C3-C4 was chosen as the treatment, that is, a double cervical implant with the purpose of stabilizing the aforementioned cervical vertebrae, using two Brazilian metal implants (Vasconcellos, 2025) in the aforementioned joint spaces.

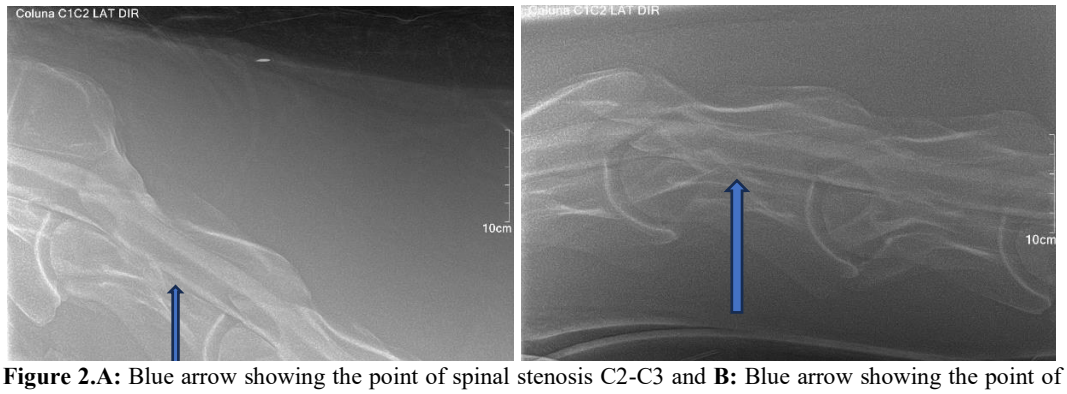

Figure 2.A: Blue arrow showing the point of spinal stenosis C2-C3 and **B:** Blue arrow showing the point of spinal compression C3-C4.

The cerebrospinal fluid removed from the dural space (60 mL) was sent for serological tests against Equine Herpesvirus type-1 (negative result), Equine Protozoal Myeloencephalitis (positive result) where it tested positive 4+ for surface antigens (SAG 2, SAG 3 and SAG 4), where we disregarded the result because in the cytology, protein and glucose exam, all these parameters were normal and therefore we believe they were residual antibodies, as Antonello et al. (2015) state that animals can remain with high antibody levels for long periods in the cerebrospinal fluid, which can last up to a year.

The surgical procedure was performed with the horse in dorsal decubitus, under general anesthesia, where an incision approximately 40 cm long was made in the central ventral region of the neck, moving the structures apart until the vertebrae could be seen, as described by Wagner et al. (1979), where the arthrodesis points were marked with needles and radiographed to then be prepared to receive the metal implants (Figures 3).

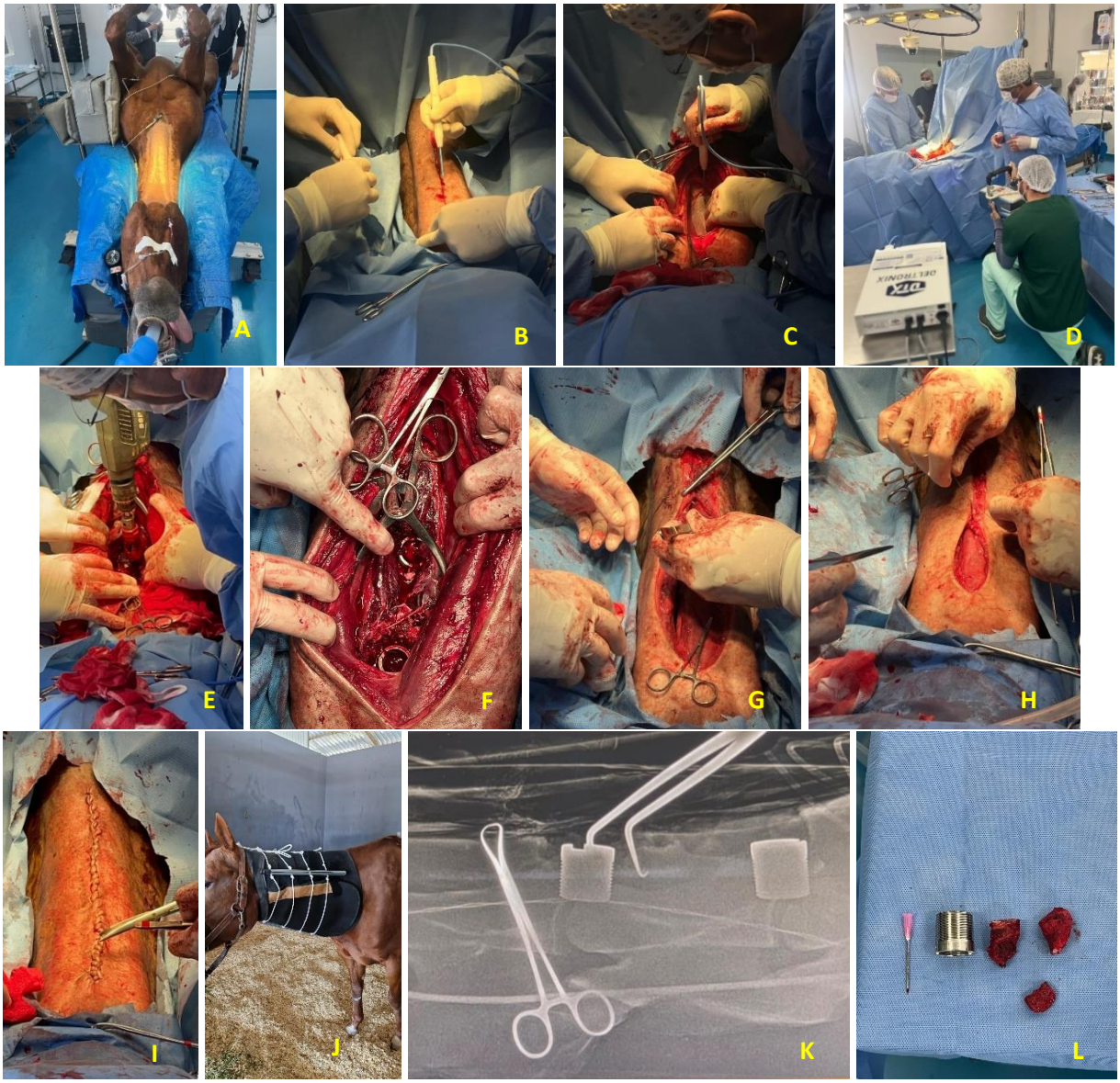

Figure 3. A: Positioning and alignment of the neck. **B:** Incision approximately 40 cm long on the ventral cervical surface. **C:** Tissue divulsion and hemostasis using an electric scalpel. **D:** Radiographic control prior to creating the "well" for placement of the threaded implants. **E:** Drilling and bone removal with a drill of the same diameter as the implant. **F:** Threading of the implants after preparation of the bone "wells." **G-I:** Closure performed in a continuous pattern, with multiple layers as needed to minimize dead space. **J:** Immobilization used postoperatively to reduce neck mobility. **K-L:** Intraoperative radiographic control and bone fragments removed for implant placement.

After drilling and creating the implant "wells," the threaded implants were inserted and their position verified radiographically (Figure 3K) to confirm proper fixation and alignment. Once implantation was completed, the surgical site was irrigated repeatedly with sterile saline solution to remove clots, bone

fragments, microbleeds, and tissue debris, as described by Vasconcellos (2025). The use of drains was avoided due to the risk of ascending infection.

Internal closure was performed using continuous sutures with number 2 Vicryl® in as many planes as necessary, with careful attention to nearby anatomical structures such as the jugular vein, carotid artery, vagus and recurrent laryngeal nerves, ventral cervical muscles, and the esophagus, avoiding excessive tension during reconstruction (Figures 3G-H). The skin was sutured using continuous nylon number 1, and the stitches were removed after three weeks.

Postoperative antimicrobial therapy included penicillin (40,000 IU twice daily for 10 days) and enrofloxacin (5 mg/kg once daily for 10 days), combined with flunixin meglumine (0.25 mg/kg for 3 days) and morphine (0.1 mg/kg every 6 hours for 3 days) for analgesia.

After 24 hours, the mare developed signs of digestive atony and abdominal discomfort. Morphine administration was discontinued, and fluid therapy (Ringer's lactate), prokinetic agents, and lidocaine were initiated for analgesia. Within 24 hours of the onset of abdominal pain and continued treatment, intestinal motility returned to normal, with no further complications observed. Feed volume was reduced, maintaining a high-fiber diet consisting of fresh grass, grass hay, and alfalfa hay.

Results and discussion

This case represents the one hundred and first cervical spinal fusion (arthrodesis) procedure performed by the team. This surgery remains highly challenging due to several factors: the complexity of the neurological diagnosis, the need for confirmation via contrast myelography, and the technical demands of cervical fusion itself. Furthermore, many of the materials and instruments required for the procedure are not yet commercially available, making the process even more difficult. Consequently, such complex diagnostic and surgical protocols are not yet routine in Brazil or in equine medicine worldwide.

In this specific case, the mare exhibited postoperative pain within the first 48 hours. The administration of morphine, even at therapeutic doses, resulted in abdominal discomfort and intestinal atony. Without prompt intervention, this condition could have progressed to the need for laparotomy and enterotomy, with a high risk of fatal outcome. Fortunately, the rapid suspension of morphine and institution of appropriate medical management prevented this complication.

No abnormal swelling or seroma formation was observed, both common postoperative complications following cervical arthrodesis. We attribute this favorable outcome to meticulous multilayer closure, performed under consistent tension to preserve anatomical alignment and minimize dead space. Additionally, thorough lavage and aspiration of the surgical site were performed repeatedly to remove debris such as bone fragments, tissue remnants, and blood clots. Careful inspection and control of microbleeding were carried out throughout the procedure to ensure hemostasis.

The mean surgical time was approximately two hours, extended slightly by preparatory steps including positioning, shaving, antisepsis, catheterization, and anesthetic monitoring. This duration could be significantly reduced with a more experienced surgical team familiar with this specialized procedure.

The combined use of penicillin and a fluoroquinolone (enrofloxacin) proved effective for infection prevention and control. However, in this case, a mild adverse reaction to enrofloxacin was observed, leading to its discontinuation on the third postoperative day, following the onset of abdominal discomfort 24 hours after surgery.

At 30 days postoperatively (Figure 4), both the surgical wound and the implants demonstrated excellent healing, with no evidence of seroma, fistula, or any other complications. This outcome confirms that the adopted protocol and the Brazilian metallic implant are both safe and effective. Notably, enrofloxacin and morphine were discontinued early, on the second postoperative day, leaving penicillin as the sole injectable therapy, without negative impact on recovery.

An important point to emphasize is the age of the operated animal. At 11 years old, this mare was considerably older than most cases treated by the team, as the majority of procedures are performed in

horses under three years of age. Despite this, the mare exhibited a reduction of one ataxia grade within the follow-up period, indicating a positive neurological response. Younger animals generally present with milder ataxia, which facilitates postoperative recovery and rehabilitation. The improvement seen in this older horse suggests that, under appropriate clinical and surgical management, cervical arthrodesis can be successful even in mature animals.



Figure 4. A: Surgical wound 30 days after surgery and **B:** showing the radiographic control of the same period.

Conclusions

We conclude that the technique originally described by Seo and later applied to horses by Wagner continues to be a valuable option for the surgical management of cervical vertebral instability. Based on the experience accumulated in more than one hundred procedures performed by the team, the method has shown consistently favorable clinical outcomes, particularly in young horses presenting grade 2–3 ataxia. Although an alternative surgical technique was subsequently developed by Vasconcellos, its use has been more limited to date, likely reflecting its recent introduction and gradual dissemination.

The Brazilian metallic implants employed in this case once again proved to be highly efficient and reliable for their intended purpose. Despite this being only the second application of this specific implant type, it showed excellent performance and safety. Its national manufacture and local availability represent a significant advancement, facilitating broader access to this technique within Brazil and potentially throughout Latin America.

References

Andrews, F. M., Matthews, H. K., & Reed, S. M. (1990). The ancillary techniques and tests for diagnosing equine neurological disease. *Veterinary Medical*, *85*, 1325–1330.

Antonello, A. M., Pivoto, F. L., Camillo, G., Braunig, P., Sangioni, L. A., Pompermayer, E., Venturini, M. C., & Vogel, F. S. F. (2015). Investigação de anticorpos contra Sarcocystis neurona e Sarcocystis cruzi em equinos. *Arquivo Brasileiro de Medicina Veterinaria e Zootecnia*, *67*(5). https://doi.org/10.1590/1678-4162-7374.

Bagby, G. W. (1988). Arthrodesis by the distraction-compression method using a stainless-steel implant. *Orthopedics*, *11*(6), 931–934. https://doi.org/10.3928/0147-7447-19880601-13.

De Lahunta, A., Glass, E., & Kent, M. (2020). De Lahunta's Veterinary neuroanatomy and clinical neurology. In *de Lahunta's Veterinary Neuroanatomy and Clinical Neurology, Fifth Edition*.

Derouen, A., Spriet, M., & Aleman, M. (2016). Prevalence of anatomical variation of the sixth cervical vertebra and association with vertebral canal stenosis and articular process osteoarthritis in the horse. *Veterinary Radiology and Ultrasound*, *57*(3), 243–258. https://doi.org/10.1111/vru.12350.

Dimock, W. W. (1950). "Wobblers" a hereditary disease in horses. *Journal of Heredity*, 319–323.

Dimock, W. W., & Errington, B. J. (1939). Incoordination of equidae: Wobblers. *Journal of the American Veterinary Medical Association*, *95*, 261–267.

Dyson, S., Quiney, L., Phillips, K., Zheng, S., & Aleman, M. (2024). Radiological abnormalities of the cervicothoracic vertebrae in Warmblood horses with primary neck-related clinical signs versus controls. *Veterinary Radiology & Ultrasound*, *65*(6), 755–768.

Errington, B. J. (1938). Causes of wobblers. *Veterinary Bulletin*, *32*(Sup.), 153–155.

Falco, M. J., Whitwell, K., & Palmer, A. C. (1976). An Investigation into the Genetics of 'Wobbler Disease' in Thoroughbred Horses in Britain. *Equine Veterinary Journal*, *8*(4), 165–169. https://doi.org/10.1111/j.2042-3306.1976.tb03331.x.

Furr, M., Jonhson, A. L., & Reed, S. (2015). *Equine Neurolgy* (2nd ed.).

Glade, M. J., & Belling, T. H. (1984). Growth plate cartilage metabolism, morphology and biochemical composition in over- and underfed horses. *Growth*, *48*(4), 473–482.

Glade, M. J., & Luba, N. K. (1987). Serum triiodothyronine and thyroxine concentrations in weanling horses fed carbohydrate by direct gastric infusion. *American Journal of Veterinary Research*, *48*(4), 578–582. https://doi.org/10.2460/ajvr.1987.48.04.578.

Hurtig, M., Green, S. L., Dobson, H., Mikuni-Takagaki, Y., & Choi, J. (1993). Correlative study of defective cartilage and bone growth in foals fed a low-copper diet. *Equine Veterinary Journal*, *25*(16 S), 66–73. https://doi.org/10.1111/j.2042-3306.1993.tb04857.x.

Knight, D. A., Gabel, A. A., Reed, S. M., Embertson, R. M., Tyznik, W. J., & Bramlage, E. R. (1985). Correlation of dietary mineral to incidence and severity of metabolic bone disease in Ohio and Kentucky. *Procedings American Association of Equine Practitioners*, 445–461.

Knight, D. A., Weisbrode, S. E., Schmall, L. M., Reed, S. M., Gabel, A. A., Bramlage, L. R., & Tyznik, W. I. (1990). The effects of copper supplementation on the prevalence of cartilage lesions in foals. *Equine Veterinary Journal*, *22*(6), 445–461. https://doi.org/10.1111/j.2042-3306.1990.tb04310.x.

Kronfeld, D. S., Meacham, T. N., & Donoghue, S. (1990). Dietary aspects of developmental orthopedic disease in young horses. *The Veterinary Clinics of North America. Equine Practice*, *6*(2), 451–465. https://doi.org/10.1016/S0749-0739(17)30551-5.

May-Davis, S. (2014). The Occurrence of a Congenital Malformation in the Sixth and Seventh Cervical Vertebrae Predominantly Observed in Thoroughbred Horses. *Journal of Equine Veterinary Science*, *34*(11–12), 1313–1317. https://doi.org/10.1016/j.jevs.2014.09.012.

May-Davis, S., Eckelbarger, P. B., Dzingle, D., & Saber, E. (2024). Characterization and Association of the Missing Ventral Tubercle(s) from the Sixth Cervical Vertebra and Transpositions on the Ventral Surface of the Seventh Cervical Vertebra in Modern *Equus ferus* caballus. *Animals*, *14*(12), 1830. https://doi.org/10.3390/ani14121830.

Mayhew, J. (2009). Tetany, tremor and postural and movement disorders. *1th International Congress of World Equine Veterinary Association*.

Nixon, A. J., & Stashak, T. S. (1988). Laminectomy for relief of atlantoaxial subluxation in four horses. *Journal of the American Veterinary Medicine Association*, *193*(6), 677–682. https://doi.org/10.2460/javma.1988.193.06.677.

Pinchbeck, G., & Murphy, D. (2001). Cervical vertebral fracture in three foals. *Equine Veterinary Education*, *13*(1), 8–12. https://doi.org/10.1111/j.2042-3292.2001.tb01874.x.

Santinelli, I., Beccati, F., Arcelli, R., & Pepe, M. (2016). Anatomical variation of the spinous and transverse processes in the caudal cervical vertebrae and the first thoracic vertebra in horses. *Equine Veterinary Journal*, *48*(1), 45–49. https://doi.org/10.1111/evj.12397.

Seo, J., Oh, J., Kim, P., Ju, C. Il, & Kim, S. W. (2023). Traumatic Anterior Cervical Disc Herniation Presenting as Severe Dysphagia. *Diagnostics*, *13*(24). https://doi.org/10.3390/diagnostics13243644.

Summers, B. A., Cummings, J. F., & De Lahunta, A. (1995). *Veterinary Neuropathology. Mosby-Year Book*. Mosby Year Book.

Vasconcellos, L. A. S. (2025). Arthrodesis Cervical (C3C4) as a Resolution of Incoordination in Foal. *16 Th Jornadas Internacionais Hospital Muralha de Évora*.

Vasconcellos, L. A. S. (1996). Artrodese Cervical em um potro. Descrição de uma Nova Técnica. *XV Congresso Panamericano de Ciências Veterinárias*, 121.

Vasconcellos, L. A. S. (1995). *Problemas neurológicos na clínica equina*. Editora Varela.

Vasconcellos, L. A. S. (2022). *Neurologia e neurocirurgia equina: Princípios gerais*. Editora Lusófona.

Vasconcellos, L. A. S. (2024). Irregularidade morfológica dos anéis traqueais em equinos associada ou não à malformação cervical. *PUBVET*, *18*(5). https://doi.org/10.31533/pubvet.v18n05e1588.

Vasconcellos, L. A. S. (2025). New Brazilian implant for cervical arthrodesis in horses. *Brazilian Journal of Research Environmental*. https://doi.org/10.34188/bjaerv8n2-036.

Veraa, S., Bergmann, W., van den Belt, A. J., Wijnberg, I., & Back, W. (2016). Ex vivo computed tomografhic evaluations of morphology variations in equine cervical vertebrae. *Veterinary Radiology and Ultrasound*, *57*(5). https://doi.org/10.1111/vru.12393.

Wagner, P. C., Bagby, G. W., Grant, B. D., Gallina, A., Ratzlaff, M., & Sande, R. (1979). Surgical Stabilization of the Equine Cervical Spine. *Veterinary Surgery*, *8*(1), 85–88. https://doi.org/10.1111/j.1532-950X.1979.tb00596.x.

Watson, A. G., & Mayhew, I. G. (1986). Familial congenital occipitoatlantoaxial malformation (OAAM) in the Arabian horse. *Spine*, *11*(4), 334–339. https://doi.org/10.1097/00007632-198605000-00007.

Histórico do artigo:
Recebido: 28 de setembro de 2025
Aprovado: 23 de outubro de 2025

Licenciamento: Este artigo é publicado na modalidade Acesso Aberto sob a licença Creative Commons Atribuição 4.0 (CC-BY 4.0), a qual permite uso irrestrito, distribuição, reprodução em qualquer meio, desde que o autor e a fonte sejam devidamente creditados.