

<https://doi.org/10.31533/pubvet.v18n05e1588>

## Morphological irregularity of tracheal rings in horses, associated or not with cervical malformation: Initial study

Luiz Alberto da Silva Vasconcellos\*  

\*Centro de Medicina Equina integrado – CEMEI. Araçatuba, São Paulo, Brasil. Correspondences, [luizalbertovasconcellos@gmail.com](mailto:luizalbertovasconcellos@gmail.com)

**Abstract.** With the purpose of verifying the existence of irregularities in the tracheal rings of horses and correlating it with the presence of equine cervical vertebral malformation, 45 horses were used, including males and females of different breeds, distributed in two groups. The first group consisted of horses with congenital cervical lesions (GI 10 animals) and the second group composed of horses with non-congenital cervical lesions (GII 35 animals). The first group consisted of horses with cervical lesions of congenital origin (GI 10 animals) and the second group composed of horses with non-congenital cervical lesions (GII 35 animals). Animals were from different parts of Brazil and treated in a private practice over the period of 2019-2023. It was observed that both horses without congenital lesions and those with congenital lesions had tracheal rings of different shapes that did not compromise air flow in the animals studied, and also that all animals with congenital lesions in the cervical vertebrae had a “ridge” in the dorsal portion of the tracheal rings. This was an initial study and we believe that further investigation should be carried out.

**Key words:** Cervical radiography, equine cervical malformation, tracheal ring anomalies

### *Irregularidade morfológica dos anéis traqueais em equinos associada ou não à malformação cervical: Estudo inicial*

**Resumo.** Com o objetivo de verificar a existência de irregularidades nos anéis traqueais de cavalos e correlacioná-la com a presença de malformação vertebral cervical equina, foram utilizados 45 cavalos, entre machos e fêmeas de raças diferentes, distribuídos em dois grupos. O primeiro grupo conformado por cavalos com lesões cervicais de origem congênita (GI 10 animais) e o segundo grupo composto por cavalos com lesões cervicais não congênitas (GII 35 animais). Os animais eram de diversas partes do Brasil, atendidos em consultório particular no período de 2019-2023. Observou-se que tanto os cavalos sem lesões congênitas quanto os com lesões congênitas apresentavam anéis traqueais de diferentes formatos que não comprometiam o fluxo de ar nos animais estudados, e também que em todos os animais com lesões congênitas nas vértebras cervicais apresentavam anéis traqueais em a porção dorsal da traqueia circunda uma “crista”. Este foi um estudo inicial e acreditamos que mais investigações devem ser realizadas.

**Palavras-chave:** Radiografia cervical, malformação cervical equina, anomalias do anel traqueal

### Introduction

The trachea of a medium-sized adult horse is made up of a cartilaginous tube (including cartilaginous rings) 70 to 80 cm long with approximately 48 to 60 rings, with the capacity for dorsal expansion thanks to its muscles (tracheal muscle), conducting air from the larynx to the bronchioles ([Hausler, 2018](#); [Hodgson & Hodgson, 2003](#); [Siger et al., 1998](#)). This anatomical structure bifurcates into two bronchi (Carina region), right and left, which in turn branch more and more within the lungs until the unit called pulmonary alveolus or alveolar sac ([Budras et al., 2003](#); [Colville, 2011](#); [Vasconcellos, 2019](#)).

Obstructive tracheal diseases or malformations are observed in neonates with non-productive cough, without other hematological and biochemical changes, as well as in middle-aged horses (tracheal collapse) with low athletic performance ([Simmons et al., 1988](#)).

Because it is also classified as a congenital disease, equine cervical vertebral compressive malformation (ECVCM or ECVM) is a developmental defect of the neck vertebrae (cervical vertebrae) that causes narrowing of the spaces in the cervical spinal canal ([Mannaa et al., 2023](#)). It results from injuries that lead to compression of the spinal cord and damage to the spinal cord tracts. One of the most common non-infectious causes of spinal ataxia in horses, CMVC is commonly called “wobbler syndrome”, as affected horses are often unstable or uncoordinated, and may be called other names such as cervical vertebral malformation, cervical vertebral instability, cervical spondylotic myelopathy and cervical spinal stenosis ([Bedenice & Johnson, 2022](#); [Pezzanite & Easley, 2019](#); [Vasconcellos, 2022](#)).

There are also spinal compressions resulting from cervical dislocations, compressions due to fractures, lateral deviations due to osteochondritis dissecans (OCD), trauma to soft tissues (muscular and cervical ligament ruptures) but these pathologies are of traumatic origin and acquired ([Mannaa et al., 2023](#); [Vasconcellos, 2022](#)).

## Materials and methods

The study was carried out over a period of 4 years (2019-2023), jockey clubs, equestrian stables, stud farms, boarding houses for horses in Brazilian territory, where all horses treated had reduced muscle strength in one or more limbs, muscular atrophies focal, hyposensitivity of the skin and limbs, ataxic (28 males and 17 females, aged from 3 to 12 years, 5 Thoroughbred horses, 30 Quarter Horses, 10 Mangalarga Marchador horses, a group with neurological problems based in the region cervical). In this study group (45 animals), 10 horses had neurological problems with non-traumatic etiology (congenital-GI) and 35 horses had acquired neurological problems (traumas, OCD, dislocations, fractures-GII), but both groups with exclusively localized neurological damage in the cervical region.

After clinical neurological examination ([Vasconcellos, 2022](#)), horses with neurological problems based in the cervical region were initially x-rayed (left or right latero-lateral position) for screening, with the purpose of separating the acquired cases (35 horses, traumas, OCD, dislocations, fractures) of the congenital cases (10 horses), and after obtaining the images, the cervical tracheal rings were also analyzed in order to verify their morphology, equality and homogeneity. Images from cervical radiographs of animals with acquired problems and those with congenital problems were used, with the aim of comparing the tracheal rings and associating changes in them with the group with congenital problems. In atypical cases of tracheal rings identified by radiography, video endoscopy images were taken in an attempt to visualize changes in the cartilaginous rings and record them when present.

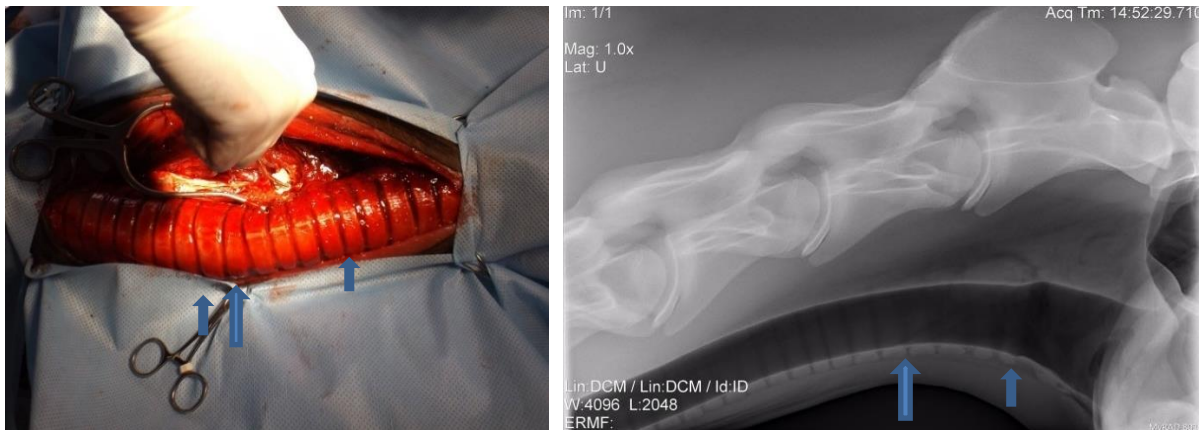## Results and discussion

According to the images in [figures 1](#) and [2](#), both in the group with congenital problems and in the group without congenital problems, there is a clear irregularity of the tracheal cartilaginous rings, which does not represent any problem of a functional nature, as the important thing is that there is no resistance to the air passed through the trachea both during exhalation and inspiration and that this finding represents only an anatomical confirmation, a fact that is very little reported whether in anatomy textbooks or findings in this scientific essay.

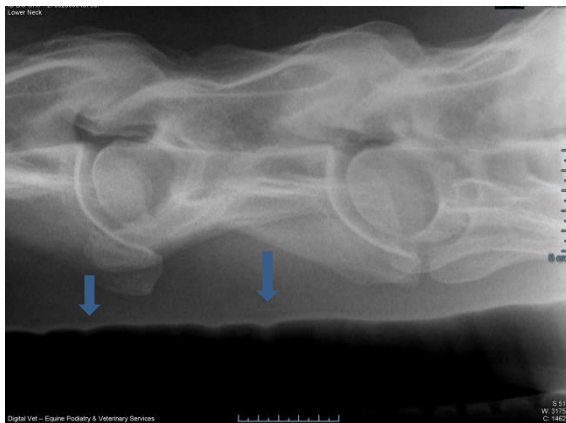
There is indeed a change in the dorsal region of the tracheal rings seen in the radiographs of GI ([Figure 3](#)) where there is the presence of a "ridge", seen in all animals in this group, not occurring in the GII group.

The image recorded by video endoscopy ([Figure 4](#)) clearly shows the change in the spaces between the rings, visualized and marked, showing a greater space between the rings, clearly showing this irregularity, but only with a visual and superficial assessment, we believe there is no interference in respiratory physiology specifically in this case. The presence of this "ridge" in the dorsal region of the tracheal rings, associated with the cervical malformation in the C6C7 vertebrae (GII), could together with the *Longus colli* muscle, compress the recurrent laryngeal nerve (left or right) causing cases of

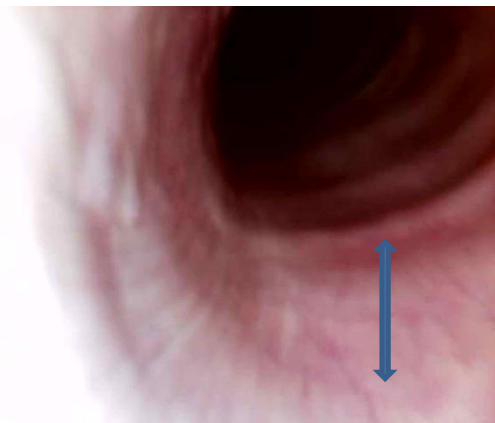
laryngeal hemiplegia ([May-Davis & Walker, 2015](#)), which we did not confirm with upper respiratory video endoscopy, because we did not perform this procedure in all horses in GII.



**Figures 1 and 2.** There is irregularity of the tracheal rings (**blue arrow**).



**Figure 3.** The tracheal rings seen in the radiographs of GI where there is the presence of a "ridge" (**blue arrows**).



**Figure 4.** Video endoscopy image showing increased space between the tracheal rings of a horse with cervical problems, non-congenital problems (**blue arrow**).

Another important clinical finding in GI and GII were brachial plexus compressions, muscle atrophies in the anterior limbs (right and left), hyposensitivity of the skin ([Figure 5A](#)) and cervical muscles ([Figure 5B](#)) ([May-Davis & Walker, 2015](#)).



**Figure 5.** **A** – Image showing complete skin hypoesthesia/anesthesia in a horse with a non-congenital cervical problem. **B** – Cervical region with complete anesthesia resulting, in this case, from a congenital lesion.

## Conclusions

The simple lateral projection radiographs initially showed that the tracheal rings in all horses from both groups are of different sizes and shapes, regardless of whether the animal has or does not have a neurological problem located in the cervical region. Irregularities in the cartilaginous rings ("ridge"), were present in all horses with congenital cervical malformations, that is, we found this lesion in all horses with congenital cervical problems in this study, but we suggest further studies using better investigation techniques. With these simple findings we can indicate the importance of radiographic examination whether for the purchase of animals that will begin high-performance athletic activity or not and in the case of animals with findings that indicate congenital problems should be prohibited from entering into a reproductive program.

## References

- Bedenice, D., & Johnson, A. L. (2022). Neurologic conditions in the sport horse. *Animal Frontiers*, 12(3). <https://doi.org/10.1093/af/vfac036>.
- Budras, K.-D., Sack, W. O., & Rock, S. (2003). *Anatomy of the horse: an illustrated text*. Mosby.
- Colville, T. (2011). *Anatomia e fisiologia clínica para medicina veterinária*. Elsevier Brasil.
- Haussler, K. K. (2018). Equine Manual Therapies in Sport Horse Practice. In *Veterinary Clinics of North America - Equine Practice* (Vol. 34, Issue 2). <https://doi.org/10.1016/j.cveq.2018.04.005>
- Hodgson, J. L., & Hodgson, D. R. (2003). Tracheal aspirates: indications, technique and interpretation. In N. E. Robinson (Ed.), *Current Therapy in Equine Medicine* (pp. 401–406).
- Mannaa, M., Shamaa, A. A., Shawky, A., Hassan, I. M., Refaey, A. M., & Abu-Seida, A. M. (2023). A novel surgical technique for treatment of cervical vertebral stenotic myelopathy (wobbler syndrome) in a filly. *Journal of Equine Veterinary Science*, 126. <https://doi.org/10.1016/j.jevs.2023.104493>.
- May-Davis, S., & Walker, C. (2015). Variations and implications of the gross morphology in the Longus colli muscle in Thoroughbred and Thoroughbred derivative horses presenting with a congenital malformation of the sixth and seventh cervical vertebrae. *Journal of Equine Veterinary Science*, 35(7). <https://doi.org/10.1016/j.jevs.2015.03.002>.
- Pezzanite, L., & Easley, J. (2019). Update on Surgical Treatment of Wobblers. In *Veterinary Clinics of North America - Equine Practice* (Vol. 35, Issue 2). <https://doi.org/10.1016/j.cveq.2019.04.002>.
- Siger, L., Hawkins, J. F., Andrews, F. M., & Henry, R. W. (1998). Tracheal stenosis and collapse in horses. In *Compendium on Continuing Education for the Practicing Veterinarian* (Vol. 20, Issue 5).
- Simmons, T., Petersen, M., Parker, J., Dietze, A., & Rebhun, W. (1988). Tracheal collapse due to chondrodysplasia in a miniature horse foal. *Equine Practice*, 10, 39–41.
- Vasconcellos, L. A. S. (2019). *Problemas respiratórios nos equinos e seus métodos de diagnóstico por imagens*. Editora MedVet.
- Vasconcellos, L. A. S. (2022). *Neurologia e neurocirurgia equina: Princípios gerais*. Editora Lusófona.

### Histórico do artigo:

**Recebido:** 19 de março de 2024

**Aprovado:** 30 de março de 2024

**Licenciamento:** Este artigo é publicado na modalidade Acesso Aberto sob a licença Creative Commons Atribuição 4.0 (CC-BY 4.0), a qual permite uso irrestrito, distribuição, reprodução em qualquer meio, desde que o autor e a fonte sejam devidamente creditados.