

<https://doi.org/10.31533/pubvet.v17n8e1428>

Metaraminol in reverting hypotension in equine anesthesia with isoflurane and dexmedetomidine: Case report

Maressa Mantovani de Lara Martins^{1*}, Thais Jassek Soares², Fabiana Gomes Ferreira Alves², Caio Veloso Silva², Cassiana Maria Garcez³, Bruna Natali da Costa⁴, Luciane Maria Laskoski⁵, João Henrique Perotta⁵

¹Graduate Student of Federal University of Paraná, Department of Veterinary Medicine. Curitiba – PR Brazil.

²Resident of Federal University of Paraná, Veterinary Hospital of the Federal University of Paraná. Curitiba – PR Brazil.

³Veterinary Doctor, Veterinary Hospital of the Jockey Club of Paraná. Curitiba – PR Brazil.

⁴Doctoral Student of Federal University of Paraná, Department of Veterinary Medicine. Curitiba – PR Brazil.

⁵University Teacher of Federal University of Paraná, Department of Veterinary Medicine. Curitiba – PR Brazil

*Corresponding author, e-mail: maressa-@hotmail.com

Abstract. Systemic hypotension is the most frequent complication of inhalational anesthesia in horses and is directly related to increased post-anesthetic morbidity and mortality. The treatment of hypotension depends on the physiological cause and can be performed with positive chronotropic, inotropic and vasopressor drugs, individually or combined. However, there are few drugs used in horses and the effects of these drugs on cardiovascular support in these animals during anesthesia are poorly described. For this reason, this study aimed to report the action of metaraminol (Aramin[®]), a vasopressor with direct and indirect action on adrenergic receptors, in the correction of hypotension in a horse submitted to elective orchiectomy, anesthetized with isoflurane and continuous infusion of dexmedetomidine. Cardiovascular changes with different infusion rates of 1, 2 and 4 µg/kg/min are described. Metaraminol reversed hypotension at a rate of 4 µg/kg/min, increasing systolic blood pressure by 93 mmHg, mean blood pressure by 74 mmHg, diastolic blood pressure by 66 mmHg, and reduced cardiac output by 7.1 L/min and heart rate to 32 bpm, in relation to mean arterial pressure of 58 mmHg, cardiac output of 13.4 L/min and heart rate of 36 bpm at the expired rate of 1.3% isoflurane. Furthermore, it improved cardiac contractility at the rate of 2 and 4 µg/kg/min and did not cause arrhythmia at any infusion rates.

Keywords: Dexmedetomidine, hypotension, horses, isoflurane, metaraminol

Metaraminol na reversão da hipotensão em anestesia equina com isoflurano e dexmedetomidina: Relato de caso

Abstract. A hipotensão sistêmica é a complicação mais frequente da anestesia inalatória em equinos e está diretamente relacionada ao aumento da morbidade pós-anestésica. O tratamento da hipotensão depende da causa fisiológica e pode ser feito com drogas cronotrópicas, inotrópicas e vasopressoras positivas, isoladamente ou em combinação. No entanto, existem poucas drogas utilizadas em equinos e os efeitos dessas drogas no suporte cardiovascular nesses animais durante a anestesia são pouco descritos. Por esse motivo, este estudo teve como objetivo relatar a ação do metaraminol (Aramin[®]), um vasopressor com ação direta e indireta nos receptores adrenérgicos, na correção da hipotensão em um equino anestesiado com isoflurano e infusão contínua de dexmedetomidina submetido à orquiectomia eletiva. São descritas alterações cardiovasculares com diferentes taxas de infusão de 1, 2 e 4 µg/kg/min. O metaraminol reverteu a hipotensão a uma taxa de 4 µg/kg/min, aumentando a pressão arterial sistólica

em 93 mmHg, a pressão arterial média em 74 mmHg e a pressão arterial diastólica em 66 mmHg e reduziu o débito cardíaco em 7,1 L/min e a frequência cardíaca em 32 bpm, em relação à pressão arterial média de 58 mmHg, débito cardíaco de 13,4 L/min e frequência cardíaca de 36 bpm, na frequência expirada de 1,3% de isoflurano. Além disso, melhorou a contratilidade cardíaca nas taxas de 2 e 4 $\mu\text{g}/\text{kg}/\text{min}$ e não causou arritmias em todas as taxas de infusão.

Palavras-chave: Dexmedetomidina, hipotensão, cavalos, isoflurano, metaraminol

Introduction

Maintenance of anesthesia in horses with volatile agents is associated with a higher risk of morbidity and mortality ([Johnston et al., 2002](#)). There is a link between the main causes of perioperative death in horses (cardiac arrest or cardiovascular depression, followed by fractures and myopathies, respectively) and inhalational anesthesia ([Johnston et al. 2002](#)). Thus, the most frequent cardiovascular complication in equine anesthesia is systemic hypotension, as anesthetic agents are vasodilators and reduce tissue perfusion, affecting cardiac output (CO) by depressing myocardial contractility and vascular smooth muscle tone. Hypotension is defined as a systolic blood pressure (SBP) less than 90 to 100 mmHg or a mean arterial pressure (MAP) less than 70 mmHg ([Daunt, 1990](#)). Prolonged hypotension caused by inhalational anesthetics is one of the factors associated with myopathy in horses, which is the main cause of morbidity and death in healthy horses in the post-anesthetic period. On the other hand, myopathies and neuropathies can be caused by the decubitus and poor positioning of the patient, since in many surgical procedures it is necessary to lay the animal in dorsal or lateral decubitus, unnatural positions that place the weight of the muscles and viscera in certain regions of the body, being able to compress important vessels and nerves ([Johnston et al., 2002](#); [Klein, 1990](#)). It is noteworthy that the highest incidence of hypotension and the worst response to treatment with dobutamine were in horses anesthetized with halothane in dorsal decubitus ([Donaldson, 1988](#)). Therefore, blood pressure monitoring is essential to prevent and reverse hypotension in anesthetized horses, and pharmacological treatment depends on the physiological cause of systemic hypotension and is performed with the administration of positive chronotropics, inotropics, vasopressors, alone or combined. However, there are few available drug options actually used in horses to maintain blood pressure ([Schauvliege & Gasthuys, 2013](#)). The search for new drugs is important for scientific innovation and the diversity of product options on the market, aiming at a better cost-benefit ratio, and it is essential to know the changes that a drug can cause in an organism, from positive support to possible adverse events. Thus, its use or not can be recommended with the correct dosage, indications and contraindications, drug interactions and precautions. This case report describes the cardiovascular changes resulting from the use of metaraminol at different infusion rates for the treatment of hypotension in a horse anesthetized with isoflurane and dexmedetomidine undergoing elective orchiectomy at the Veterinary Hospital of the Federal University of Paraná.

Bibliographic review

Hypotension

Adequate tissue oxygenation is essential to avoid complications or deaths associated with general anesthesia in horses. The mechanisms involved in oxygen supply are illustrated in [figure 1](#) and include the physiological factors that determine blood pressure and tissue oxygen supply ([Schauvliege & Gasthuys, 2013](#)).

The reduction of MAP implies the reduction of tissue perfusion affecting tissue oxygenation ([Schauvliege & Gasthuys, 2013](#)). According to [Wagner \(2008\)](#), hypotension is the most frequent complication in inhalational anesthesia in horses. This is due to the greater sensitivity of these animals to the vasodilator effect of inhalational anesthetics, which can lead to post-anesthetic myopathy which is responsible for 7% to 44% of anesthesia-related deaths [Senior \(2013\)](#). [Richey et al. \(1990\)](#) demonstrated that there is a significant correlation between hypotension and postoperative claudication, when MAP is less than 70 mmHg. Sustained hypotension and cardiovascular depression

reduce blood flow and tissue perfusion, which implies post-anesthetic myopathy (Klein, 1990; Richey et al., 1990).

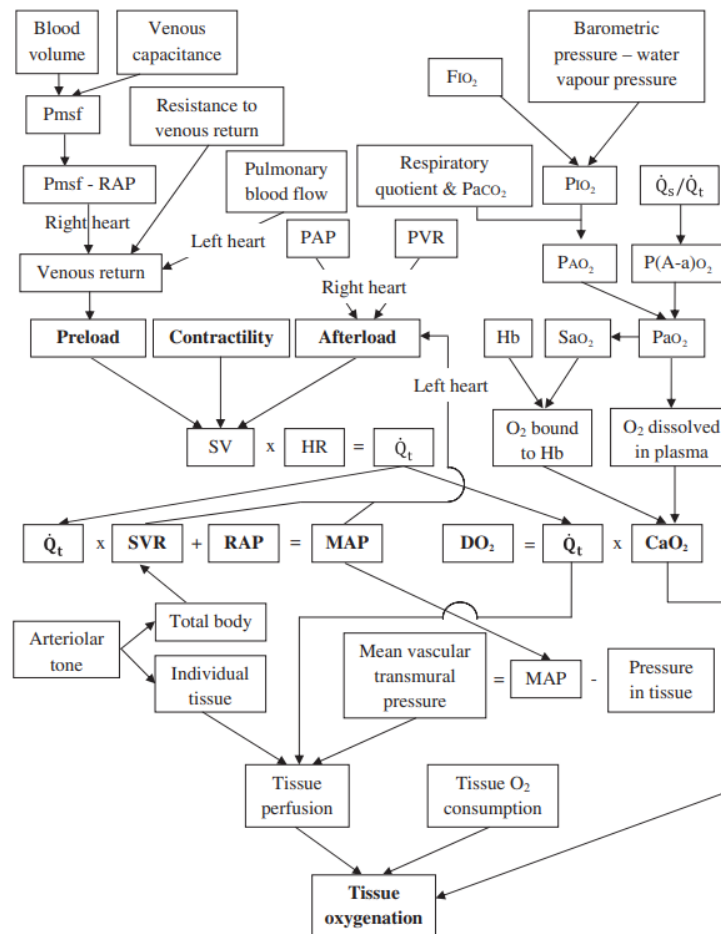


Figure 1. Factors that determine tissue oxygenation. CaO₂, arterial oxygen content; DO₂, oxygen supply; FIO₂, inspiratory fraction of oxygen; Hb, hemoglobin concentration; HR, heart rate; MAP, mean arterial pressure; P(A-a)O₂, alveolar-arterial oxygen difference; PAO₂, alveolar oxygen tension; PaO₂, arterial oxygen tension; PAP, pulmonary artery pressure; PIO₂, inspiratory oxygen tension; Pmsf, mean systemic filling pressure; PVR, pulmonary vascular resistance; Q_s/Q_t, venous mixing fraction; Q_t, cardiac output; RAP, right atrial pressure; SaO₂, arterial oxygen saturation; SV, stroke volume; SVR, systemic vascular resistance. Source: [Schauvliege & Gasthuys \(2013\)](#).

Some are the causal factors of hypotension during inhalational anesthesia in horses. Isoflurane acts on β -adrenergic receptors and causes a dose-dependent reduction in peripheral vascular resistance (PVR) associated with a reduction in CO (Hawkey et al., 2022). In addition, it depresses vascular smooth muscle reactivity by preventing the action of norepinephrine and KCl, as it reduces Ca²⁺ mobilization and the sensitivity of myofilaments to Ca²⁺ by inhibiting voltage-gated Ca²⁺ channels (Akata et al., 2003). It also depresses myocardial contractility, by reducing the activation of the myofibrillar enzyme Mg²⁺-ATPase activity-Ca²⁺ and directly affecting the proteins myosin, actin and myosin light chain, thus affecting the sensitivity of the myofilament to Ca²⁺ and decreasing its contraction in the cardiac trabecular muscle (Meng et al., 2016). In addition, some drugs used for induction such as guaicol glyceryl ether (GGE) and ketamine may possibly also be associated with temporary and persistent hypotension in horses (Guedes & Natalini, 2002). Other causes of hypotension are changing from lateral to dorsal decubitus, hemorrhage and intermittent positive pressure ventilation (IPPV), which can impair venous return, decreasing preload and consequently reducing CO and MAP (Guedes & Natalini, 2002; Klein, 1990; Schauvliege & Gasthuys, 2013). Furthermore, there are reflex vagal responses to stimulation of the urinary bladder, the transverse facial nerve during cannulation of the transverse facial artery, traction of the ovarian pedicle or spermatic cord, pressure or traction of the eye, and forced extension of contracted joints, which can induce a clinical picture of hypotension, bradycardia or asystole (Klein, 1990). Clinical treatment for hypotension did not significantly reduce the incidence of post-anesthetic myopathy or change the

quality of recovery, but the severity of myopathy was less in horses treated with fluid therapy and dobutamine infusion ([Young & Taylor, 1993](#)). Therefore, monitoring of blood pressure and adequate treatment of hypotension are essential during anesthesia in horses, and the ideal MAP should be at least 70 mmHg ([Klein, 1990](#); [Wagner, 2008](#)).

Drugs for hypotension treatment

Clinical resolution of hypotension during anesthesia encompasses four approaches ([Wagner, 2008](#)):

1. Decrease the administration of hypotensive agents;
2. Increase the administration of intravenous fluids;
3. Administer inotropic drugs;
4. Administer vasopressors.

To better understand blood pressure management, it is necessary to understand physiology. Remembering that MAP can be determined as follows:

Equation 1: $MAP = CO \times PVR$

Equation 2: $MAP = (HR \times SV) \times PVR$

In which, the MAP is equal to the CO multiplied by the PVR, still in turn the CO is given by the multiplication of the heart rate (HR) and systolic volume (SV). In this way, we can adjust MAP by increasing HR, SV and PVR ([Boesch, 2013](#)). The first effective treatment to solve hypotension is to reduce the anesthetic depth and, consequently, the vasodilator effect of general anesthetics (approach 1). The second step involves the administration of intravenous fluid to improve tissue perfusion, for which it is necessary to infuse fluid at a rate of 10 mL/kg/h for maintenance, but if the animal is dehydrated, the volume of fluid administered is determined by the degree of dehydration times the weight in kg of the animal (approach 2). However, some patients are not responsive and the next step is pharmacological treatment ([Boesch, 2013](#); [Daunt, 1990](#); [Wagner, 2008](#)). To improve CO, it is necessary to increase the HR and the force of myocardial contraction, in this way bradycardia can be treated by performing the approach (1) if the animal is in a deep anesthetic plane or administering intravenously (IV) atropine (0.01–0.02 mg/kg) or glycopyrrolate (0.005–0.01 mg/kg) ([Boesch, 2013](#); [Daunt, 1990](#); [Wagner, 2008](#)). These two antimuscarinic drugs have a positive chronotropic effect. However, their use requires caution, as in horses they reduce intestinal motility, which can lead to colic and/or discomfort abdominal ([Schauvliege & Gasthuys, 2013](#)). SV is determined by preload, myocardial contractility and afterload ([Boesch, 2013](#); [Daunt, 1990](#)). In anesthesia, there are some factors that affect the SV, due to the reduction of myocardial contractility for some reasons: 1. Excessive elimination of CO₂ when intermittent ventilation with positive pressure is performed, since CO₂ stimulates the sympathetic nervous system to increase contractility myocardial; 2. Intermittent positive pressure ventilation can also affect left ventricular preload by reducing SV, especially in hypovolemic horses; 3. Myocardial dysfunction can occur in animals with sepsis and in horses with colic; 4. anesthetics (eg inhalational), endotoxemia and electrolyte disturbances. Therefore, to correct myocardial contractility, approaches 1 and 2 can be performed, or the administration of positive inotropic drugs (dobutamine, ephedrine and Ca²⁺) and the treatment of endotoxemia ([Boesch, 2013](#)).

Inotropics

Treatment with inotropes in horses is performed mainly with dobutamine infusion (1-4 µg/kg/min). Dobutamine is an α₁, β₁ and β₂ adrenergic receptor agonist, with the predominant β₁ action responsible for increasing cardiac output and, consequently, increasing MAP. This synthetic catecholamine also has β₂-agonist effects that cause vasodilation and PVR reduction. The action of dobutamine improves tissue perfusion and blood flow in skeletal muscle, its efficacy is proven, with a short action time and rapid onset of action, it is a safe drug when used with caution in horses ([Boesch, 2013](#); [Muir & McGuirk, 1987](#); [Schauvliege & Gasthuys, 2013](#); [Wagner, 2008](#)). If the dose of dobutamine to raise MAP causes tachycardia or the horse does not respond to its effects, for example, endotoxemic horses with low PVR, ephedrine (0.06 – 0.12 mg/kg) is an alternative, as in addition to its inotropic effect, its vasoconstrictor action can induce increase in PVR and blood pressure by its direct and indirect action on α₁, β₁ and β₂ adrenergic receptors, inducing release of presynaptic

norepinephrine stock, increasing HR, contractility. It has a long duration of action compared to other catecholamines, but it takes time to start acting. Its use in tachycardia horses should be done cautiously, due to the risk of further increasing the HR ([Boesch, 2013](#); [Muir & McGuirk, 1987](#); [Schauvliege & Gasthuys, 2013](#); [Wagner, 2008](#))

Vasopressors

Approach four is recommended only when there is intense vasodilation and when the other recommendations already mentioned have failed. The use of vasopressors is indicated when hypotension is caused by a decrease in PVR (eg, induced by endotoxemia or drugs), but the CO and myocardial contractility remain normal or high, with the aim of reestablishing or maintaining the vessel tone, restoring the vascular transmural pressure ([Boesch, 2013](#); [Muir & McGuirk, 1987](#); [Schauvliege & Gasthuys, 2013](#); [Wagner, 2008](#)). Vasopressors increase the intracellular Ca^{2+} concentration in vascular smooth muscle cells, causing vasoconstriction, raising MAP by increasing PVR. Some sympathomimetic drugs act on α_1 receptors linked to G protein on vascular smooth muscle cells, which when stimulated activate the alpha subunit, which activates the phospholipase C cascade and ultimately increases protein phosphorylation and releases intracellular Ca^{2+} , with norepinephrine usually being the first line of choice ([Boesch, 2013](#); [Muir & McGuirk, 1987](#); [Schauvliege & Gasthuys, 2013](#); [Wagner, 2008](#)). Norepinephrine (3 $\mu\text{g}/\text{kg}$) acts on α_1 and α_2 receptors, and an additional effect on β_1 receptors, its action time is short, from one to two minutes due to its short half-life (20 to 30 seconds), it increases contractility, but can decrease CO by increasing PVR ([Schauvliege & Gasthuys, 2013](#)). Phenylephrine (0.25–2 $\mu\text{g}/\text{kg}/\text{min}$) is a selective α_1 agonist, with little effect on β -adrenergic receptors in the heart, in horses and ponies it elevates PVR, MAP, central venous pressure and hematocrit, without improving muscle blood flow. It is used when contraction of the spleen is required in the treatment of nephrosplenic entrapment of the large colon in horses ([Schauvliege & Gasthuys, 2013](#)).

Metaraminol

Metaraminol is a vasopressor with direct effect on vascular adrenergic receptors and stimulates norepinephrine release (indirect action), with proven efficacy in maintaining SVB at close to baseline values in spinal anesthesia for cesarean section in women and associated with less neonatal acidosis, lower incidence of nausea or vomiting, compared to the use of ephedrine, in addition to allowing a higher umbilical arterial pH than phenylephrine ([Chao et al., 2019](#); [Harrison et al., 1963](#); [Schauvliege & Gasthuys, 2013](#)).

Metaraminol (Aramine[®]) induces a strong change in SBP and right ventricular contraction force; increasing the concentration of norepinephrine in the blood of the coronary sinus and systemic arteries. Moreover, it showed that norepinephrine stores are depleted in the atrial appendage in dogs ([Harrison et al., 1963](#)). The duration of effects of metaraminol in humans, when used as an intravenous bolus (0.5-5 mg) is between 20-60 min with onset of action between 1-2 min, having a better lead time than phenylephrine, in addition can be administered intramuscularly lasting between 1 – 1.5 h at a dose of 2-10 mg ([Nag et al., 2015](#)). Metaraminol was tested in crossbred dogs, after the administration of levomepromazine, at a dose of 0.1 mg/kg diluted in 0.9% saline solution (0.5 mL total volume), making it possible to prove its action in reversing the hypotension caused by phenothiazine and in maintaining SBP at values close to baseline ([Nunes et al., 1995](#)). [Bolzan et al. \(1998\)](#) described the maintenance of intraocular pressure in dogs anesthetized with halothane using metaraminol, in continuous infusion, at doses of 2 and 5 $\mu\text{g}/\text{kg}/\text{min}$. The dose of 2 $\mu\text{g}/\text{kg}/\text{min}$ maintained the intraocular pressure at physiological values, remembering that the mean intraocular pressure and blood pressure demonstrate a significant correlation ([Bolzan et al., 1998](#)). Furthermore, metaraminol administered at a dose of 0.2 mg/kg in splenectomized mongrel dogs during IPPV at a level that induces cardiovascular depression substantially increased CO, MAP and central blood volume ([Braunwald et al., 1957](#)).

With the aim of investigating cardiovascular alterations in dogs anesthetized with isoflurane and halothane, [Tucker et al. \(1974\)](#) compared high doses of various vasopressors and metaraminol produced more ventricular and supraventricular arrhythmias in the group anesthetized with halothane.

Incidentally, metaraminol did not significantly affect the MAC (minimum alveolar concentration) in dogs anesthetized with halothane, and among the seven vasopressors used, it was the one that most raised MAP at a dose of 3 µg/kg/min together with phenylephrine (4 µg/kg/min) in continuous infusion (Steffey & Eger, 1975). In a literature review, carried out between from 02/19/2022 to 05/31/2023, in the SciELO, ScienceDirect, Pubmed, Google Scholar databases, using the keywords: metaraminol, equine hypotension, horses. There were no found references describing the use of metaraminol in maintaining blood pressure in anesthetized horses. However, this review supports that metaraminol hemitartrate is a potent vasopressor with positive effects and may be a therapeutic possibility in reversing hypotension in horses during general anesthesia.

Clinical case report

A male equine, 3 years and 6 months old, belonging to the Military Police of Paraná (Coronel Dulcídio Regiment), crossbred, weighing 432 kg (scale weight) and with a zaino coat, was referred to the Veterinary Hospital from the Federal University of Paraná (HV/UFPR) to undergo orchiectomy using the closed technique on May 3, 2023. The anamnesis of the equine patient carried out on 02/04/2020 at the HV/UFPR reports that the animal has lost sight in one eye since December 31, 2019, and the equine patient was born on 11/04/2019. Furthermore, at the time, the patient had an immunosuppression crisis and presented opacity in both eyes, which was treated, and the diagnosis was determined as a corneal ulcer by the responsible veterinary resident. Before the surgical procedure, a preanesthetic evaluation was performed, whose clinical parameters are described in [Table 1](#). On the preoperative morning, venous blood was collected for blood count and biochemical tests.

Tabela 1. Clinical parameters at rest of the equine patient in the pre-anesthetic evaluation for a closed technique orchiectomy procedure at HV/UFPR.

Clinical parameters	Values
Heart rate (HR)/min	40 bpm
Respiratory Rate (RR)/min	28 rpm
Gut motility of the four quadrants	++
Ileocecal discharge	1/3 min
Body temperature (°C)	37,3 °C
Capillary refill time (CRT)	2 sec
Skin turgor	1 sec
Oral mucosa	normocorada
Behaviour	alerta, agitado
Comments	fezes amolecidas e presença de secreção nasal mucopurulenta

Observations: the animal was fasting for 24 hours of concentrate, fasting for 8 hours for roughage and fasting for 4 hours of water.

The equine patient in the evaluation presented blindness with corneal opacity in the left eye and asymmetry with projection outwards in relation to the right eye when the equine was observed frontally (buphthalmos) ([Figure 2A](#)).

The animal was classified according to the anesthetic risk as ASA II. The anesthetic technique chosen was partial intravenous anesthesia (PIVA). IV (intravenous) xylazine (0.5 mg/kg) was used for preanesthetic medication (MPA) and anesthetic induction was performed with ketamine (2.2 mg/kg) and guaiaicol glyceryl ether (50 mg/kg). After anesthetic induction, the patient was placed in the supine position to perform the orchiectomy using the adapted closed technique ([Dias et al., 2021](#); [Santos & Pimentel, 2023](#)), with adequate padding and immobilization to minimize the risk of complications ([Figure 2B](#)).

Monitoring of physiological parameters was performed with a multiparametric monitor (LifeWindow 9x MRI, Digicare, United States,). HR and cardiac rhythm were obtained using electrocardiography in lead II; peripheral oxyhemoglobin saturation (SpO₂) was obtained with the sensor positioned on the patient's tongue; invasive blood pressure was obtained by connecting the pressure circuit previously filled with heparinized solution to the catheter positioned in the right facial artery, the transducer was positioned at heart level (considering the shoulder level as a reference) and the ambient pressure was set to zero; ETCO₂ and expired fraction of isoflurane were evaluated by the gas analyzer of the device with a side stream module and the line was connected to the Y part of the anesthetic circuit ([Figure 2C](#)). The patient was maintained under mechanical ventilation, in volume-

controlled mode, with a tidal volume of 10 mL/kg, I:E ratio of 1:4, inspiratory time of 2 seconds and maximum inspiratory peak pressure of 20 cmH₂O. Anesthesia was maintained with isoflurane (Isoflurine®, Cristália, Itapira, SP, Brazil) diluted in oxygen and continuous infusion of dexmedetomidine, 1 µg/kg/h (Dexdomitor, Zoetis, Campinas, SP, Brazil). When there were signs of superficialization of the anesthetic plane, ketamine 0.11 mg/kg (Cetamin, Syntec, Hortolândia, SP, Brazil) and xylazine 0.11 mg/kg (Xylazine 10%, Dechra, Rio de Janeiro, RJ, Brazil) in bolus. In addition, an intratesticular block was performed with 20 mL of 2% lidocaine without vasoconstrictor for each testicle and subcutaneous infiltration of the scrotal skin.

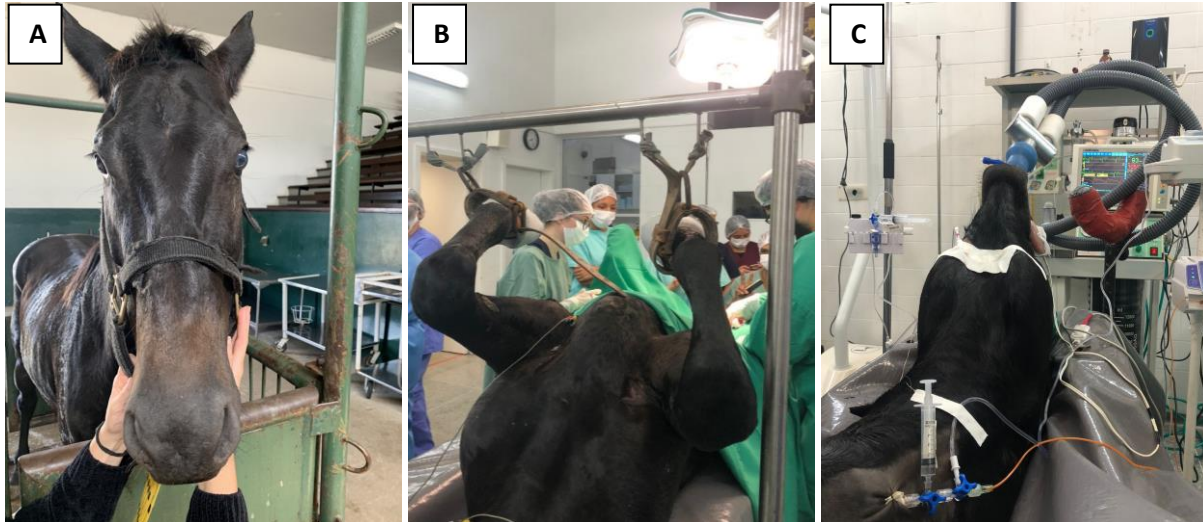

Figure 2. A: Equine patient in the pre-anesthetic evaluation in the amphitheater of the HV – UFPR. B: Equine patient positioned in dorsal decubitus maintained under general anesthesia in the large animal surgical center at HV – UFPR for a closed technical orchiectomy procedure. C: Equine patient in dorsal decubitus maintained under general anesthesia in the HV – UFPR, with recording of vital parameters and invasive pressure. Source: HV/UFPR-Curitiba (2023).

The drug of choice for treating hypotension was metaraminol hemitartrate (Aramin®, Cristália, Itapira, SP, Brazil), starting with 1 µg/kg/min and increasing to 2 µg/kg/min and 4 µg/kg/min, as required. Before and after the start of vasoactive infusion, cardiorespiratory and echocardiographic parameters were recorded. Echocardiographic parameters were obtained by transthoracic echocardiography (Affiniti 50®, Philips, Bothell, WA, United States) in the right parasternal window (Figure 3). The infusions were prepared in lactated Ringer's solution, in 60 mL syringes and administered through a DigiPump™ SR8x syringe pump (Digicare Biomedical, United States) for the continuous infusion of dexmedetomidine and UniFusion SP50 (Vet Shenzhen MedRena Biotech, China) for metaraminol infusion.

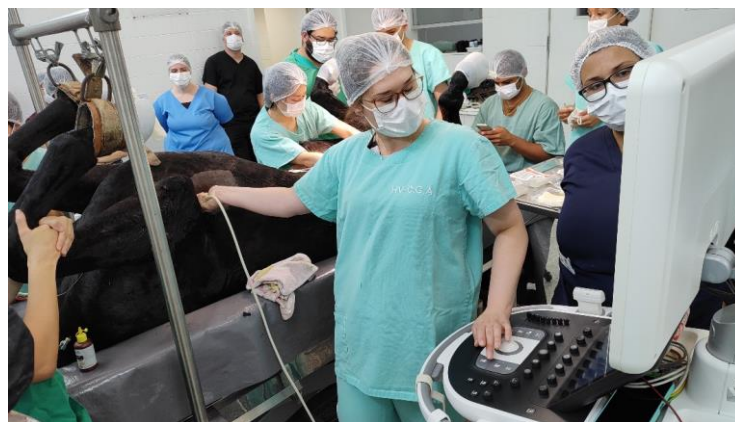

Figure 3. Echocardiography of an equine patient in the large animal surgical center of the HV – UFPR. Source: HV/UFPR-Curitiba (2023).

The oculopalpebral and anal reflexes, the presence or absence of nystagmus and lacrimation, eyeball rotation and pupil dilation were constantly evaluated by the anesthetist to verify the anesthetic

plane in which the animal was. In order to determine whether there was alteration in tissue perfusion by the administration of metaraminol, lactate was measured immediately after the end of the continuous infusion at a rate of 4 µg/kg/min and again the morning after the procedure, in the postoperative period. PVR was calculated using the following formula, adapted because central vascular pressure (PVC) was not measured:

Correct equation by software: $PVR = (MAP - PVC) \times 79.92 / CO$ (ScyMed®, Houston, TX, United States).

Adapted equation: $PVR = MAP / CO \times 79.92$.

Results and discussion

The horse had mild anemia (Ht 30%) and possibly an infection and/or an allergic condition by observing its white series with 27% of toxic neutrophils with mild cytoplasmic basophilia and moderate toxic granulation, in addition to 5% of reactive lymphocytes and rare granular lymphocytes, in addition basophils were at the upper limit, suggesting an allergic condition. Incidentally, their AST and GGT enzymes were also increased, indicating an abnormality, as elevated GGT is indicative of cholestasis. These alterations can be justified by the stress of transport, added to its clinical parameters (soft feces and the mucopurulent secretion observed in the upper airways) and its history of living in the pasture with other animals (transmission of pathogens), the horse possibly had a picture of parasitosis and infection and/or allergy in the respiratory tract, which should be investigated with complementary tests, such as coproparasitological examination and bronchoalveolar lavage (Feitosa, 2014). Furthermore, the equine patient possibly had glaucoma secondary to uveitis, as demonstrated by his history and physical evaluation. As a complementary exam, the intraocular pressure could have been evaluated (Wilkie & Gilger, 2004). Therefore, the patient was classified as ASA II, which are animals that have mild systemic disease according to the physical state (Tranquilli et al., 2013). The results of the erythrogram, leukogram and biochemical laboratory tests are presented in tables 2, 3 and 4, respectively.

Table 2. Equine patient's erythrogram request 05/03/2023.

Erythrogram	Results		Values of reference	
Erythrocytes	7,16 milhões /mm ³	6,8	a	12,9
Hemoglobin	10,20 g/dl	11	a	19
Hematocrit	30,00%	32	a	53
RDW	0,00%	0	a	0
V.C.M	41,90 u ³	37	a	59
H.C.M	14,25 pg	0	a	0
C.H.C.M	34,00 g/dl	31	a	37
Total protein	7,60 g/dl	6,2	a	7,9
Erythroblasts	0,00%			
Red series remarks	Fibrinogen: 0,4 g/dL.			

Source: HV/UFPR-Curitiba (2023).

Table 3. Equine patient's leukogram, request 05/03/2023.

Leukogram	Results	Relative Reference Value	Absolute Reference Value	
Leukocytes	8700 /mm ³		5500	a 14300
Myelocytes	0 /mm ³	0-0%	0	a 0
Metamyelocytes	0 /mm ³	0-0%	0	a 0
Immature neutrophils	0 /mm ³	0-0%	0	a 100
Mature neutrophils	47% 4089 /mm ³	41-60%	2260	a 8580
Eosinophils	4% 348 /mm ³	0-6%	0	a 1000
Basófilos	2% 174 /mm ³	0-2%	0	a 290
Typical lymphocytes	46% 4002 /mm ³	27-53%	1500	a 7700
Atypical lymphocytes	0% 0 /mm ³	0-0%	0	a 0
Monocytes	1% 87 /mm ³	0-6%	0	a 1000
Others	0% 0 /mm ³			
Remarks white series	27% toxic neutrophils with mild cytoplasmic basophilia and moderate granulation toxic. 5% reactive lymphocytes and rare granular lymphocytes.			
Platelet counting	105000 mil/m ³		10000	a 35000

Source: HV/UFPR-Curitiba (2023).

The equine patient took a long time to enter the anesthetic plane, so it was necessary to perform three boluses of 1 ml of ketamine/xylazine. Vital parameters and anesthetic interferences are represented in [chart 1](#) during the procedure until the end of anesthesia.

Table 4. Equine patient biochemistry, request on 05/03/2023.

	Results		Reference Value	
Creatine	1,00 mg/dL	1,20	a	1,90
Urea	44,00 mg/dL	21,40	a	51,30
GGT	18,90 UI/L	4,30	a	13,40
AST	610,0 UI/L	226,00	a	366,00

Source: HV/UFPR-Curitiba (2023).

Chart 1. Anesthetic chart with vital parameters of the equine patient anesthetized with isoflurane, continuous intravenous infusion of dexmedetomidine and treated with metaraminol at rates of 1, 2 and 4 µg/kg/min to control transanesthetic hypotension. (Continue)

© Start of surgery					× Surgery end		
Time	14:15	14:20	14:30	14:35	14:40	14:45	14:49
V%	1,2	1	1	1,5	1,3	1,3	1,3
HR	37	34	33	39	36	36	36
SBP	NA	NA	100	95	85	75	75
MAP	NA	NA	77	75	65	62	58
SBP	NA	NA	71	69	58	51	51
R _R	8	8	8	8	8	8	8
SpO ₂	99	99	98	99	99	99	99
ETCO ₂	35	31	32	40	40	42	40
Event	1		1		1		2
	• End of the anesthesia				Σ Extubation		
Time	14:52	14:53	14:56	15:00	15:02	15:05	15:08
V%	1,3	1,3	1,6	1,5	1,7	1,7	1,4
HR	37	37	36	36	35	33	31
SBP	75	77	75	80	83	87	93
MAP	58	59	56	61	52	60	74
DBP	47	47	48	50	63	68	66
R _R	8	8	8	8	8	8	8
SpO ₂	99	99	98	98	98	99	97
ETCO ₂	40	40	43	41	43	44	42
Event			3		4		5
Time	15:10	15:15	15:20	15:25	15:30	15:35	15:40
V%	1,4	1,2	1,2	1,1	1,2	1,3	1,3
HR	34	30	31	31	32	33	34
SBP	97	107	105	118	113	96	87
MAP	80	94	96	103	97	80	76
DBP	73	88	89	89	89	72	70
R _R	8	8	8	8	8	8	8
SpO ₂	98	97	97	98	98	97	97
ETCO ₂	45	43	45	43	33	41	30
Event	©	6					*
Time	15:45	15:50	15:55	16:00	16:05	16:10	16:15
V%	1,2	1,2	1,2	1,3	1,1	1,5	1,4
HR	34	35	34	33	31	31	33
SBP	84	80	83	86	97	115	108
MAP	73	73	71	74	73	101	94
DBP	66	66	64	67	65	92	88
R _R	8	8	8	8	8	8	8
SpO ₂	97	98	97	98	98	98	98
ETCO ₂	42	45	45	44	45	44	45
Event							

Chart 1. Anesthetic chart with vital parameters of the equine patient anesthetized with isoflurane, continuous intravenous infusion of dexmedetomidine and treated with metaraminol at rates of 1, 2 and 4 µg/kg/min to control transanesthetic hypotension. (Continuation).

© Start of surgery					× Surgery end		
Time	16:20	16:25	16:30	16:35	16:40	16:45	16:50
V%	1,1	1,3	1,6	1,5	1,5	1,2	1,4
HR	32	60	32	32	32	32	32
PAS	105	120	96	86	96	109	112
MAP	95	109	76	74	73	85	100
PAD	89	102	67	66	63	80	91
R _R	8	8	8	8	8	8	NA
SpO ₂	98	97	98	98	98	98	98
ETCO ₂	42	49	46	44	47	43	24
Event							7 e 1
Time	16:53	16:56	16:59	17:00	17:08	18:20	
V%	1,4	NA	NA	NA	NA	NA	
HR	35	NA	NA	34	35	NA	
PAS	120	NA	NA	NA	NA	NA	
MAP	105	NA	NA	NA	NA	NA	
PAD	96	NA	NA	NA	NA	NA	
R _R	5	NA	NA	NA	NA	NA	
SpO ₂	98	NA	NA	98	98	NA	
ETCO ₂	46	NA	NA	NA	NA	NA	
Event	8	×		9	•	Σ	

Abbreviations: V%, end-tidal isoflurane concentration; HR, heart rate; SBP, systolic blood pressure; MAP, mean arterial pressure; DBP, diastolic blood pressure; R_R, respiratory rate; SpO₂, peripheral oxyhemoglobin saturation; ETCO₂, end-tidal carbon dioxide tension; NA, not applicable. Event: 1, 1 mL bolus (ketamine/xylazine); 2, start of metaraminol infusion at a rate of 1 µg/kg/min; 3, start of metaraminol infusion at a rate of 2 µg/kg/min; 4, start of metaraminol infusion at a rate of 4 µg/kg/min; 5, decrease in metaraminol infusion rate to 1 µg/kg/min; 6, end of metaraminol infusion; 7, return of spontaneous breathing; 8, end of dexmedetomidine infusion; 9, Urethral sounding; *MAP normalization 25 min after the end of metaraminol infusion. Source: HV/UFPR-Curitiba (2023).

Cardiovascular changes and echocardiographic parameters were recorded with the expired fraction of isoflurane at 1.5% (T1); fraction expired isoflurane at 1.3% (T2); with metaraminol infusion rate of 1 µg/kg/min infusion (T3), 2 µg/kg/min (T4) and 4 µg/kg/min (T5) (Table 5).

When MAP was 58 mmHg, metaraminol administration was started at a rate of 1 µg/kg/min, maintained for 6 min and 30 sec (T3). During this period, no change in HR was observed in relation to the baseline HR evaluated when the expired concentration of isoflurane was 1.3% (Table 5) and the MAP increased by only 1 mmHg, 4 min after starting the infusion and then decreased again (Table 1). However, the CO decreased approximately 29.8% and there was a slight decrease in FS by 17.25% and EF by 14.74% in relation to T2 (Table 5). Then, the metaraminol infusion rate was increased to 2 µg/kg/min (T4), observing a transient increase in MAP to 61 mmHg, but with a subsequent decrease to 52 mmHg. This assessment also registered a slight decrease in HR from 36 to 34 bpm and a reduction of approximately 44.7% in CO, in addition to an increase in FS by 9.21% and EF by 8.03% in relation to T2 (Table 5). To normalize MAP, the metaraminol infusion rate was increased to 4 µg/kg/min and at 5 min 38 sec (T5), MAP finally increased to 74 mmHg. In this assessment, it was also recorded that systolic blood pressure and mean blood pressure increased, with correction of hypotension at the end of the infusion (Chart 1), with a reduction in CO of approximately 47%, a decrease in HR from 36 to 32 bpm and an increase in EF in 21.42% and FS in 26.29% in relation to T2 (Table 5). Once MAP normalized, the metaraminol infusion rate was reduced to 1 µg/kg/min and maintained for approximately 7 minutes and then stopped once MAP rose considerably to 94 mmHg. After 25 minutes of interruption of metaraminol administration, MAP stabilized at 76 mmHg. No arrhythmias were recorded on the electrocardiogram throughout the monitoring period during anesthesia and during the use of metaraminol. Metaraminol also possibly did not negatively alter tissue perfusion, as shown by the comparison of lactate values during the procedure, which was 1.70 mmol/L - after stopping metaraminol infusion at a rate of 4 µg/kg/min, and at postoperative morning of 1.50 mmol/L (Table 6), but it is important to emphasize that lactate should have been measured

before the procedure. This slight difference between values can be explained by the use of dexmedetomidine in continuous infusion, which has already been shown to significantly increase lactate and decrease PaO₂ in horses anesthetized with isoflurane and continuous infusion of dexmedetomidine at a rate of 1.75 µg/kg/h (Sleiman et al., 2016).

Table 5. Echocardiographic measurements Echocardiographic variables of the equine patient anesthetized with isoflurane, infusion continuous intravenous dexmedetomidine and treated with metaraminol at rates of 1, 2 and 4 µg/kg/min to control transanesthetic hypotension.

Echocardiographic measures	T1	T2	T3	T4	T5
AE (mm)	83,7	94,5	88,5	88,5	87,5
Ao (mm)	65,4	65,3	64,6	67,5	63,4
AE/Ao	1,28	1,45	1,37	1,31	1,38
Lung flow velocity (cm/s)	61,1	61,3	53,8	60,8	57,8
Lung flow gradient (mmHg)	1	2	1	1	1
E-septo (mm)	7,6	16		12,2	7,6
RVAWd (mm)	17,3	14,5	15,3	16,8	13,7
RVIDd (mm)	31,9	45	42,7	42,7	40,4
IVSd (mm)	18	24,4	25,2	24,4	24,4
LVIDd (mm)	76,5	82,4	79,3	80,9	80,9
LVPWd (mm)	17,3	22,1	23,6	19,8	23,6
IVSs (mm)	23,3	28,2	30,5	34,3	32
LVIDs (mm)	56,6	63,3	64,1	60,3	57,2
LVPWs (mm)	27,9	31,3	29,7	32,8	34,3
HR (bpm)	34	36	36	34	32
EDV (mL)	312	368	338	353	353
FS (%)	26	23,2	19,2	25,5	29,3
EF (%)	49,7	44,8	38,2	48,4	54,4
CO (L/min)	10,6	13,4	9,4	7,4	7,1
MAP (chart 1)	75	58	59	61	74
PVR (calculated)	573,01	345,92	501,62	658,8	832,96
HR (electrocardiogram - chart 1)	39	36	37	36	31
Remarks	Discrete insufficiency of the aortic, mitral and pulmonary valves				

Abbreviations: LA (mm), left atrial diameter; Ao (mm), aorta diameter; LA/Ao, left atrium/aorta ratio; E- septum (mm), distance from point E to the septum; RVAWd (mm), right ventricular free wall in diastole; RVIDd (mm), diameter of the right ventricular cavity in diastole. IVSd (mm), interventricular septum in diastole; LVIDd (mm), left ventricular cavity diameter in diastole; LVPWd (mm), left ventricular free wall in diastole; IVSs (mm), interventricular septum in systole; LVIDs, left ventricular cavity diameter in systole; LVPWs (mm), left ventricular free wall in systole; CO, cardiac output. HR, heart rate; EDV (ml), end-diastolic volume; EF, left ventricular ejection fraction; FS, left ventricular shortening fraction; MAP, mean arterial pressure; PVR, peripheral vascular resistance; HR, heart rate; T1, time 1 - baseline record when the isoflurane level was 1.5%; T2, time 2 - baseline record when the isoflurane rate was 1.3% (1 MAC); T3, time 3 - recording during the administration of metaraminol at the rate of 1 µg/kg/min; T4, time 4 - recording during the administration of metaraminol at the rate of 2 µg/kg/min; T5, time 5 - recording during metaraminol administration at the rate of 4 µg/kg/min. Source: HV/UFPR-Curitiba (2023).

Table 6. Result of the lactate measurement of the equine patient anesthetized with isoflurane, continuous intravenous infusion of dexmedetomidine and treated with metaraminol at rates of 1, 2 and 4 µg/kg/min to control transanesthetic hypotension.

	Lactate	Values of reference		
During surgery	1,70 mmol/L	1,11	a	1,78
Post-op morning	1,50 mmol/L	1,11	a	1,78

Source: HV/UFPR-Curitiba (2023).

These data suggest that metaraminol increases PVR, increases the force of heart contraction and reduces CO and HR. Possibly, the inotropic and vasopressor mechanism of metaraminol would be the release of norepinephrine in tissues and in the heart, as described in Harrison et al. (1963). The results are in agreement with Sarnoff et al. (1954), metaraminol improved myocardial contractility and led to bradycardia in dogs anesthetized with morphine-chloralose-urethane and agree with Malmcrona et al. (1964) on the hemodynamic effects of metaraminol in humans, HR reduction and MAP increase. The decrease in HR would possibly be a consequence of the vagal reflex that limits the increase in blood pressure, when the anesthetized dogs were vagotomized, the reflex bradycardia caused by the use of metaraminol was eliminated (Sarnoff et al., 1954), added to the effect of the continuous infusion of dexmedetomidine that reduces HR and raises SBP and MAP in certain periods during PIVA in horses (Sleiman et al., 2016). Furthermore, it can be inferred that the use of dexmedetomidine at a dose of 1 µg/kg/min does not induce an increase in blood pressure and does not prevent hypotension. However,

it is not known whether it can interfere with the effects of metaraminol, apparently not, but it is not known how the parameters would behave without dexmedetomidine infusion. The reduction in CO was important, 47%, probably due to the increase in PVR and the reduction in HR, there is no way to say that this did not affect tissue perfusion.

Conclusion

This clinical case report suggests that metaraminol (Aramin®) may be a vasopressor option in the treatment of intraoperative hypotension, as it normalized mean arterial pressure in a horse anesthetized with isoflurane and continuous infusion of dexmedetomidine at an infusion rate of 4 µg/kg/min, with substantial change in cardiac output and slight reduction in heart rate. Finally, further studies are needed to investigate the hemodynamic changes of metaraminol hemitartrate in the cardiovascular support of hypotensive horses and to compare its effects with other inotropic and vasopressor drugs during general anesthesia in horses.

References

- Akata, T., Kanna, T., Yoshino, J., & Takahashi, S. (2003). Mechanisms of direct inhibitory action of isoflurane on vascular smooth muscle of mesenteric resistance arteries. *Anesthesiology*, *99*(3), 666–677. <https://doi.org/10.1097/00000542-200309000-00023>.
- Boesch, J. M. (2013). Anesthesia for the horse with colic. *The Veterinary Clinics of North America. Equine Practice*, *29*(1), 193–214. <https://doi.org/10.1016/j.cveq.2012.11.005>.
- Bolzan, A. A., Laus, J. L., Nunes, N., & Andrade, C. P. (1998). Effects of metaraminol bitartrate on intraocular pressure in dogs under halothane anesthesia. *Veterinary Ophthalmology*, *1*(2–3), 115–118. <https://doi.org/10.1046/j.1463-5224.1998.00025.x>.
- Braunwald, E., Binion, J. T., Morgan Junior, W. L., Sarnoff, S. J., & Anderson Junior, W. (1957). Alterations in central blood volume and cardiac output induced by positive pressure breathing and counteracted by metaraminol (Aramine). *Circulation Research*, *5*(6), 670–675. <https://doi.org/10.1161/01.RES.5.6.670>.
- Chao, E., Sun, H. L., Huang, S. W., Liao, J. H., Ma, P. L., & Chen, H. C. (2019). Metaraminol use during spinal anaesthesia for caesarean section: a meta-analysis of randomised controlled trials. *International Journal of Obstetric Anesthesia*, *39*, 42–50. <https://doi.org/10.1016/j.ijoa.2019.01.009>.
- Daunt, D. A. (1990). Supportive therapy in the anesthetized horse. *Veterinary Clinics of North America: Equine Practice*, *6*(3), 557–574. [https://doi.org/10.1016/S0749-0739\(17\)30531-X](https://doi.org/10.1016/S0749-0739(17)30531-X).
- Dias, L. F., Martins, A. C. S., Pazini, A. D., Batista, G. P., Correa, T. H. C., & Nogueira, V. J. M. (2021). Orquiectomia em equinos: Técnicas cirúrgicas e suas complicações. *Brazilian Journal of Development*, *7*(12), 110097–110106. <https://doi.org/10.34117/bjdv7n12-005>.
- Donaldson, L. L. (1988). Retrospective assessment of dobutamine therapy for hypotension in anesthetized horses. *Veterinary Surgery*, *17*(1), 53–57. <https://doi.org/10.1111/j.1532-950X.1988.tb00275.x>.
- Feitosa, F. L. F. (2014). *Semiologia veterinária: A arte do diagnóstico*. Roca Ltda.
- Guedes, A. G. P., & Natalini, C. C. (2002). Anestesia em equinos com síndrome cólica: análise de 48 casos e revisão de literatura. *Ciência Rural*, *32*(535–542). <https://doi.org/10.1590/S0103-84782002000300028>.
- Harrison, D. C., Chedsey, C. A., & Braunwald, E. (1963). Studies on the mechanism of action of metaraminol (Aramine). *Annals of Internal Medicine*, *59*(3), 297–305. <https://doi.org/10.7326/0003-4819-59-3-297>.
- Hawkley, T. F., Preston, M., & Maani, C. V. (2022). *Isoflurane*.
- Johnston, G. M., Eastment, J. K., Wood, J. L. N., & Taylor, P. M. (2002). The confidential enquiry into perioperative equine fatalities (CEPEF): mortality results of Phases 1 and 2. *Veterinary Anaesthesia and Analgesia*, *29*(4), 159–170. <https://doi.org/10.1046/j.1467-2995.2002.00106.x>.

- Klein, L. (1990). Anesthetic complications in the horse. *Veterinary Clinics of North America: Equine Practice*, 6(3), 665–692. [https://doi.org/10.1016/S0749-0739\(17\)30537-0](https://doi.org/10.1016/S0749-0739(17)30537-0).
- Malmcrona, R., Schröder, G., & Werkö, L. (1964). Hemodynamic effects of metaraminol: I. Normal subjects. *American Journal of Cardiology*, 13(1), 10–14. [https://doi.org/10.1016/0002-9149\(64\)90216-4](https://doi.org/10.1016/0002-9149(64)90216-4).
- Meng, T., Bu, W., Ren, X., Chen, X., Yu, J., Eckenhoff, R. G., & Gao, W. D. (2016). Molecular mechanism of anesthetic-induced depression of myocardial contraction. *The FASEB Journal*, 30(8), 2915. <https://doi.org/10.1096%2Ffj.201600290RR>.
- Muir, W. W., & McGuirk, S. (1987). Cardiovascular drugs: Their pharmacology and use in horses. *Veterinary Clinics of North America: Equine Practice*, 3(1), 37–57. [https://doi.org/10.1016/S0749-0739\(17\)30690-9](https://doi.org/10.1016/S0749-0739(17)30690-9).
- Nag, D. S., Samaddar, D. P., Chatterjee, A., Kumar, H., & Dembla, A. (2015). Vasopressors in obstetric anesthesia: A current perspective. *World Journal of Clinical Cases: WJCC*, 3(1), 58. <https://doi.org/10.12998%2Fwjcc.v3.i1.58>.
- Nunes, N., Pompermayer, L. G., Pirolo, J., & Rahal, S. C. (1995). Emprego do metaraminol no bloqueio da hipotensão produzida pelo uso da levomepromazina em cães. *Brazilian Journal of Veterinary Research and Animal Science*, 32(2), 120–124. <https://doi.org/10.11606/issn.1678-4456.bjvras.1994.52099>.
- Richey, M. T., Holland, M. S., McGrath, C. J., Dodman, N. H., Marshal, D. B., Court, M. H., & Seeler, D. C. (1990). Equine post-anesthetic lameness: A retrospective study. *Veterinary Surgery*, 19(5), 392–397. <https://doi.org/10.1111/j.1532-950X.1990.tb01216.x>.
- Santos, B. O., & Pimentel, M. L. (2023). Orquiectomia em equinos: Revisão. *PUBVET*, 17(1), 1–7. <https://doi.org/10.31533/pubvet.v17n01a1335>.
- Sarnoff, S. J., Case, R. B., Berglund, E., & Sarnoff, L. C. (1954). Ventricular function: V. The circulatory effects of aramine; mechanism of action of “vasopressor” drugs in cardiogenic shock. *Circulation*, 10(1), 84–93. <https://doi.org/10.1161/01.CIR.10.1.84>.
- Schauvliege, S., & Gasthuys, F. (2013). Drugs for cardiovascular support in anesthetized horses. *Veterinary Clinics: Equine Practice*, 29(1), 19–49. <https://doi.org/10.1016/j.cveq.2012.11.011>.
- Senior, J. M. (2013). Morbidity, mortality, and risk of general anesthesia in horses. *Veterinary Clinics: Equine Practice*, 29(1), 1–18. <https://doi.org/10.1016/j.cveq.2012.11.007>.
- Sleiman, M., Dinev, D., & Simeonova, G. (2016). The effects of dexmedetomidine continuous rate infusion (cri) on isoflurane anaesthesia in healthy horses. *International Journal of Clinical Medicine*, 7(6), 371–380. <https://doi.org/10.4236/ijcm.2016.76040>.
- Steffey, E. P., & Eger, E. I. (1975). The effect of seven vasopressors on halothane MAC in dogs. *British Journal of Anaesthesia*, 47(4), 435–438. <https://doi.org/10.1093/bja/47.4.435>.
- Tranquilli, W. J., Thurmon, J. C., & Grimm, K. A. (2013). *Lumb and Jones' veterinary anesthesia and analgesia*. John Wiley & Sons.
- Tucker, W. K., Rackstein, A. D., & Munson, E. S. (1974). Comparison of arrhythmic doses of adrenaline, metaraminol, ephedrine and phenylephrine during isoflurane and halothane anaesthesia in dogs. *BJA: British Journal of Anaesthesia*, 46(6), 392–396. <https://doi.org/10.1093/bja/46.6.392>.
- Wagner, A. E. (2008). Complications in equine anesthesia. *Veterinary Clinics of North America: Equine Practice*, 24(3), 734–752. <https://doi.org/10.1016/j.cveq.2008.10.002>.
- Wilkie, D. A., & Gilger, B. C. (2004). Equine glaucoma. *Veterinary Clinics: Equine Practice*, 20(2), 381–391. <https://doi.org/10.1016/j.cveq.2004.04.002>.
- Young, S. S., & Taylor, P. M. (1993). Factors influencing the outcome of equine anaesthesia: a review of 1,314 cases. *Equine Veterinary Journal*, 25(2), 147–151. <https://doi.org/10.1111/j.2042-3306.1993.tb02926.x>.

Article History:

Received: July 8, 2023

Accepted: July 23, 2023

License information: This is an open-access article distributed under the terms of the Creative Commons Attribution License 4.0, which permits unrestricted use, distribution, and reproduction in any medium, provided the original work is properly cited.